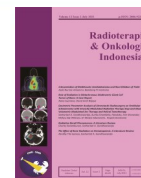



Radioterapi & Onkologi Indonesia

Journal of the Indonesian Radiation Oncology Society



Role of Radiation in Metachronous Multicentric Giant Cell Tumor of Bone: A Case Report

Nana Supriana, David Andi Wijaya

Department of Radiation Oncology, Faculty of Medicine Universitas Indonesia, Dr. Cipto Mangunkusumo Hospital, Jakarta, Indonesia

Article informations:

Received: June 2021

Accepted: July 2021

Correspondence:

Nana Supriana

E-mail:

nanasupriana2307@gmail.com

Abstract

Introduction:

Giant cell tumor of the bone (GCTB) is a rare benign locally aggressive tumor. Surgical resection whenever feasible is the treatment of choice for GCTB.

Case Presentation:

In this report, the author will review a case of well locally controlled postoperative GCTB on left ilium bone after adjuvant radiation was delivered, with a metachronous lesion on the right calcaneus and distal tibia which appeared 9 years later.

Conclusions:

Radiation either in the adjuvant setting or definitive in unresectable lesion could bring adequate local control.

Keywords: giant cell tumor of bone, radiation, metachronous, multicentric

Copyright ©2021 Indonesian Radiation Oncology Society

Introduction

Approximately 4-5% of all primary bone tumor cases are giant cell tumors of the bone (GCTB).¹ GCTB is a locally destructive benign tumor with a monostotic tumor lesion, which usually appears at the metaphyseal part of the long bone. In the adult, the knee is the predilection (95% of patients are above 25 years).² Being characteristically benign, GCTB has the ability for adjacent soft tissue invasion, angiovascular invasion, and lung metastases. The incidence of polyostotic lesions is unexpectedly rare, with an incidence of less than 1% of total cases. A metachronous lesion is even rarer. In this case report, we would like to show a reader about metachronous multicentric GCTB.

In Indonesia, GCTBs are generally found in females aged 20-29 years old and males aged around 32 years old. According to Gunasegaran et al., the most frequent

location of GCTB is the distal femur, while zygoma, mandibula, vertebrae, and zygoma is the least frequent.³

Case Presentation

A 12 years old girl came with intermittent left pelvic pain in 2010 as her chief complaint. This patient has no history of trauma, and from a former pelvic radiograph, a fractured left ilium with osteolytic bone appearance was observed.

Magnetic resonance imaging (MRI) examination was performed and showed a geographical lytic, expansive, septated lesion pathologic fracture involving left iliac bone/fossa, extended until ischium and left the acetabular roof, extended to gluteus medius and minimus muscles along with left piriformis muscles, suspicion of giant cell tumor, with differential

diagnosis of an aneurismal bone cyst. No adenopathy of the obturator, iliac, or superficial inguinal was observed.

She had undergone a subtotal resection (debulking surgery). Pathology examination ruled out any malignancy. Muscle tissue, connective tissue, and osteoid tissue with osteoblastic rimming, which was partly mineralized were observed in the obtained specimen, which could match callus tissue, were also observed.

After the operation, the patient was referred to the Department of Radiation Oncology, Dr. Cipto Mangunkusumo Hospital (RSCM) and CT simulation was performed. A lytic expansive residual lesion in the left wing of the ilium was observed. Radiation of 25 x 2 Gy using a 3D technique was delivered to this patient at the left ilium (see **Figure 1**). The pain was reduced gradually after the radiation course has been delivered. Four months after the radiation was delivered to the pelvic region, the patient had no more complaints of pain. Pelvic radiographic examination still showed a lesion with a sclerotic border, but no sign of expansion. In 2019, the patient complained of right foot pain spreading to the left leg. From the radiograph examination, a new lesion was revealed at the right tibia and right calcaneus. The orthopedic surgeon performed a curettage at the right calcaneus and bone grafting, along with the lateral side of the right tibia curettage. From the curettage specimen, a tibial tumor mass that suggests a giant cell tumor of the bone was revealed from the anatomy pathology examination. From the calcaneus, no pathological significance was recognized. This patient was once more referred to the Department of Radiation Oncology RSCM.

By the end of the year 2019, this patient received radiation at the distal tibia and calcaneus region. The radiation of 25 x 2 Gy was delivered using 2D AP-PA

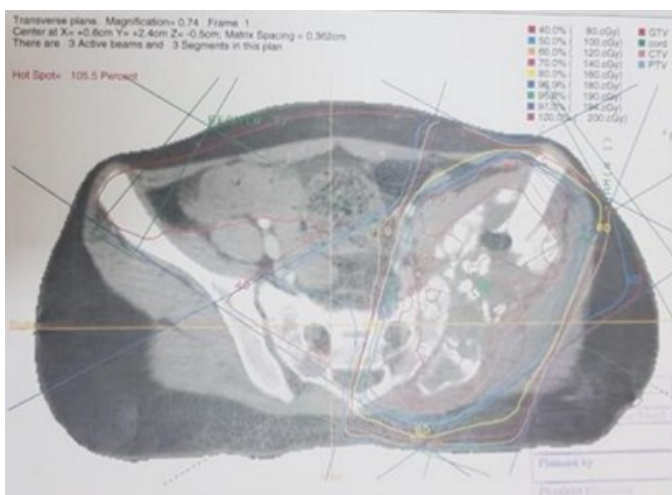


Figure 1. Radiation planning using 3D technique aimed at left pelvic region.

(anteroposterior-posteroanterior) technique (see **Figure 2**). This patient was treated using 6-MV photon in our linear accelerator device. Fixation for the right foot was achieved using both “polyurethane fixation” (PUfix) at the bottom side and the thermoplastic mask above combined.

Discussion

Clinical Presentation

The most common symptom experienced by GCTB patient is pain. Pathological fracture and skin ulceration are also signs of GCTB. Multicentric GCTB is considered synchronous if multicentricity is found in 6 months or less from the first lesion detected. Metachronous GCTB is diagnosed for multicentricity after more than six months from the initial lesion.^{4,5}

Mutation detection of H3F3A could be used as a diagnostic tool to differentiate GCTB from other tumors that contain giant cells.⁶ Specific mutation at histone 3.3 of the H3F3A gene (p.Gly34) has already been identified in around 92% of GCTB. Some mutation subsets could be recognized using mutation-specific antibody G34W.⁷

Treatment

Surgical resection is the treatment of choice, either in mono-ostotic GCTB or multicentric GCTB. Surgery should be performed wherever possible, except if surgery will cause morbidity.

Several systemic medications are available. Bisphosphonates are one amongst, which showed

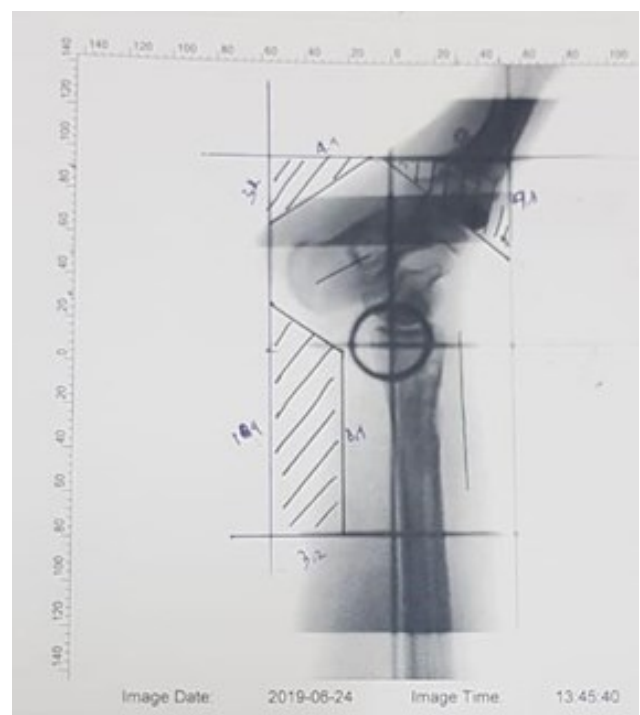


Figure 2. Radiation planning using 2D technique for the right distal tibia and calcaneus region.

neoplastic stromal cell inhibition and apoptosis effect, and also osteogenic differentiation in in-vitro and animal studies.⁸⁻¹¹

Inhibitor RANK-RANKL Denosumab for inhibiting osteoclast formation and activity is another treatment of options. Denosumab only indirectly targets the neoplastic stromal cell population, therefore there is concern about the regrowth of GCTB after the termination of the Denosumab. Nevertheless, in 2019 Poudel et al. reported the administration of Denosumab in multicentric GCTB with a good result, no disease progression in 2 years in one of the reported cases.¹²

Shi et al. reported the use of radiation treatment in 34 patients in the year 2013. They noted adequate local control of 81% in the dose range of 25-55 Gy (median 45 Gy). Radiation was delivered using Cobalt-60 with two standards, 1.6-2.33 Gy/fraction (median 1.8 Gy), or with hyperfractionation method 1.2 Gy/fraction twice daily. Local recurrence occurred in six patients, 4 of which arose in the irradiated area and could be well-managed by salvage resection.¹³

In their publication, Miszczyk et al. reported that total dose escalation does not correlate with local control. A dose of 40-45 Gy is effective, especially for tumors less than 4 cm.¹⁴ Identical findings were reported by Caudell, which stated that there is no dose-response relationship.¹⁵ Nevertheless, Ruka et al. reported that a median dose of 56 Gy could give local control until 84% in 5 years.

In this patient, diagnosis of metachronous multicentric GCTB was made because the new lesion of GCTB at the calcaneus region and right distal tibia appeared 9 years (more than 6 months) after the initial lesion at the left ilium bone. The surgeon has attempted to resect the lesion, but a residual lytic expansive destructive lesion was still left at the left ilium so that we considered giving an adjuvant treatment of radiation (25 x 2 Gy). A total dose of 50 Gy has been proven effective in this case for ensuring local control for at least 9 years observation period.

Regrettably, a metachronous lesion appeared in the right distal tibia and calcaneus region. Radiation of 25 x 2 Gy was delivered using the 2D AP-PA technique. After the radiation course was completed, this patient was educated to be checked routinely, in order to ascertain the local control and to detect any possibility of new lesions emergence.

Conclusion

Delivery of radiation of 25 x 2 Gy as a postoperative adjuvant has been proven as an effective strategy for relieving pain after subtotal resection of giant cell

tumor of the bone lesion and also for achieving adequate local control.

Conflicts of Interest

The authors declare no competing interest in this study.

References

1. Czerniak B, editor. Dorfman and Czerniak's bone tumors. Philadelphia: Elsevier; 2013.
2. Flanagan AM, Larousserie F, O'Donnell PG, Yoshida A. Giant cell tumour of bone. In: WHO classification of tumours editorial board, editors. Soft tissue and bone tumors. Lyon: International Agency for Research on Cancer; 2020.
3. Gunasegaran K, Irawan MNSB, Yantiasetiasti A. Epidemiology of giant cell tumor in Dr. Hasan Sadikin General Hospital Bandung from 2010-2013. *Althea Med J*. 2016;3(2):244-7.
4. Tandra VS, Kotha KMR, Satyanarayana MG, Vadlamani KV, Yerravalli V. Synchronous multicentric giant cell tumour of distal radius and sacrum with pulmonary metastases. *Case Rep Oncol Med*. 2015;2015:1-5.
5. Hoch B, Inwards C, Sundaram M, Rosenberg A. Multicentric giant cell tumor of bone. *J Bone Jt Surg*. 2006;88(9):1998-2009.
6. Behjati S, Tarpey PS, Presneau N, Scheipl S, Pillay N, Van Loo P, et al. Distinct H3F3A and H3F3B driver mutations define chondroblastoma and giant cell tumor of bone. *Nat Genet*. 2013 Dec;45(12):1479-82.
7. Amary F, Berisha F, Ye H, Gupta M, Gutteridge A, Baumhoer D, et al. H3F3A (Histone 3.3) G34W immunohistochemistry. *Am J Surg Pathol*. 2017 Aug;41(8):1059-68.
8. Lau CPY, Wong KC, Huang L, Li G, Tsui SKW, Kumta SM. A mouse model of luciferase-transfected stromal cells of giant cell tumor of bone. *Connect Tissue Res*. 2015 Nov;56(6):493-503.
9. Chang SS, Suratwala SJ, Jung KM, Doppelt JD, Zhang HZ, Blaine TA, et al. Bisphosphonates may reduce recurrence in giant cell tumor by inducing apoptosis. *Clin Orthop Relat Res*. 2004 Sep;426:103-9.
10. Lau CPY, Huang L, Wong KC, Kumta SM. Comparison of the anti-tumor effects of denosumab and zoledronic acid on the neoplastic stromal cells of giant cell tumor of bone. *Connect Tissue Res*. 2013 Nov;54(6):439-49.
11. Yang T, Zheng X-F, Li M, Lin X, Yin Q-S. Stimulation of osteogenic differentiation in stromal cells of giant cell tumour of bone by zoledronic acid. *Asian Pacific J Cancer Prev*. 2013 Sep;14(9):5379-83.
12. Poudel RR, Verma V, Tiwari A. Multicentric giant cell tumor (GCT) of bone treated with denosumab alone: A report of two cases. *J Clin Orthop Trauma*. 2019;10(6):1050-3.
13. Shi W, Indelicato DJ, Reith J, Smith KB, Morris CG, Scarborough MT, et al. Radiotherapy in the management of giant cell tumor of bone. *Am J Clin Oncol*. 2013 Oct;36(5):505-8.

14. Miszczyk L, Wydmański J, Spindel J. Efficacy of radiotherapy for giant cell tumor of bone: given either postoperatively or as sole treatment. *Int J Radiat Oncol.* 2001 Apr;49(5):1239–42.

15. Caudell JJ, Ballo MT, Zagars GK, Lewis VO, Weber KL, Lin PP, et al. Radiotherapy in the management of giant cell tumor of bone. *Int J Radiat Oncol.* 2003 Sep;57(1):158–65.