



# Radioterapi & Onkologi Indonesia

Journal of the Indonesian Radiation Oncology Society



## Dosimetric Parameter Analysis of Stereotactic Radiosurgery on Vestibular Schwannoma with Intensity-Modulated Radiation Therapy Step-and-Shoot, Volumetric-Modulated Arc Therapy and Helical Tomotherapy

Soehartati A. Gondhowiardjo, Aurika Sinambela, Handoko, Arie Munandar, Wahyu Edy Wibowo, Sri Mutya Sekarutami, Angela Giselsvania

Department of Radiation Oncology, Faculty of Medicine Universitas Indonesia, Dr. Cipto Mangunkusumo Hospital, Jakarta, Indonesia

Article informations:

Received: June 2021

Accepted: July 2021

Correspondence:

Soehartati A. Gondhowiardjo

E-mail:

gondhow@gmail.com

### Abstract

**Introduction:** Stereotactic Radiosurgery (SRS) is a non-invasive modality option in management of vestibular schwannoma. There is limited study comparing dosimetric parameters between three SRS techniques in vestibular schwannoma cases, which are Intensity-Modulated Radiation Therapy Step and Shoot (IMRT-SS), Volumetric Modulated Arc Therapy (VMAT), and Helical Tomotherapy (HT).

**Aim:** To compare the dosimetry parameters on SRS between IMRT-SS, VMAT, and HT techniques on Vestibular Schwannoma.

**Method:** Treatment planning with IMRT-SS, VMAT, and HT on eleven CT plan data for vestibular schwannoma cases. The marginal dose is 12 Gy with single fraction.

**Results:** Mean tumor size was  $8.23 \text{ cm} + 5.08 \text{ cm}^3$ . No significant differences were found in the mean CI, GI, V100%, and V50% among three techniques. There was no significant difference in maximal dose to brainstem, ipsilateral cochlea, optic chiasm, ipsilateral and contralateral optic nerves between the three techniques. There was significant difference of maximum dose on contralateral cochlea between IMRT-SS and VMAT techniques ( $p = 0.03$ ). The longest beam-on time was obtained with HT technique ( $1209.18 + 390.20$  second), followed by IMRT-SS technique ( $665.05 + 73.40$  second), and the shortest was with VMAT technique ( $362.87 + 24.55$  second). There was significant difference in mean monitor unit (MU) and beam on time between three techniques ( $p < 0.01$ ).

**Conclusion:** VMAT technique could be an option for SRS of vestibular schwannoma cases to provide conformity and gradient index as well as IMRT-SS and HT techniques, with better sparing to contralateral cochlea compared to IMRT-SS technique, and provides shorter beam-on time compared to IMRT-SS and HT.

**Keywords:** vestibular schwannoma, IMRT-Step and Shoot, VMAT, helical tomotherapy

Copyright ©2021 Indonesian Radiation Oncology Society

### Introduction

Vestibular Schwannoma (VS) is a benign tumor originating from Schwann cells of the VIII cranial nerve, which grows in the inner ear canal or extends to cerebellopontine angle.<sup>1</sup> The most common clinical symptoms are hearing loss, tinnitus and imbalance. If the tumor has affected the trigeminal and facial nerves, numbness and facial paralysis can occur.<sup>1,2</sup>

The diagnosis of VS is mainly based on the result of magnetic resonance imaging (MRI) with contrast. Koos in 1977 classified VS into four stages based on the size, extension, and compression of the brain stem by the tumor.<sup>3</sup> Audiometry examination is commonly performed as most patients present with hearing loss.<sup>1,4</sup> At present, there are three modalities for VS management, namely surgery, irradiation with stereotactic radiosurgery (SRS) or stereotactic

radiotherapy (SRT), or observation using serial MRI. The treatment selection depends on the age, performance status, clinical symptoms, tumor size and patient preference.<sup>1</sup> Although the surgical technique in VS has become more advanced, serious complications such as facial paralysis, stroke, cerebrospinal fluid leakage, meningitis, and persistent pain are still quite frequent. Currently for a symptomatic  $<3 \text{ cm}$ /Koos I - III tumor, the preferred therapy is SRS/SRT.<sup>4,5</sup>

The SRS provides high dose of irradiation in one irradiation therapy so it is ablative. Currently for a VS case, a 12-13 Gy marginal dose is given in one irradiation (single fraction). Radiobiologically,  $>10 \text{ Gy}$  irradiation dose in one fraction not only will directly cause the necrosis of tumor cells, but also damage the tumor vascularization, resulting in a decrease condition

of intratumoral environment, causing ischemia and a subsequent death of tumor cells within a few days after SRS.<sup>6,7</sup>

The SRS can be delivered using a system based on Gamma Knife® or based on Linear Accelerator (LINAC) devices. Several techniques can be carried out on SRS to increase conformity and avoid radiation exposure to critical organs, including the Intensity-Modulated Radiation Therapy Step-and-Shoot (IMRT-SS) technique, Volumetric-Modulated Arc Therapy (VMAT) and Helical Tomotherapy (HT) techniques. To date, there have been no studies comparing dosimetric parameters among these three SRS techniques in vestibular schwannoma cases. The purpose of this study was to analyze whether there were significant differences in Conformity Index (CI), Gradient Index (GI), V100%, V50%, maximal dose (Dmax) in the brain stem, ipsilateral and contralateral cochlea, optic chiasm, ipsilateral and contralateral optic nerves, the duration of irradiation, total monitor unit (MU) among IMRT Step-and-Shoot, VMAT and HT techniques in SRS on vestibular schwannoma cases.

## Method

This research was an explorative experimental study of eleven CT plan imaging data of patients with vestibular schwannoma at the Department of Radiation Oncology, National Referral Hospital in Indonesia to compare the dosimetry parameters on SRS among IMRT-SS, VMAT, and HT techniques. This research was conducted from January to June 2018.

The inclusion criteria were: CT plan data of patients with a diagnosis of VS who had MRI imaging data with pre-radiation contrast and CT plan data of VS patients with stage I - III according to Koos classification or equivalent to tumor with diameter <3 cm or volume <13.5 cm<sup>3</sup>. The exclusion criteria were: CT plan data of patients with bilateral vestibular schwannoma and CT plan data of postoperative vestibular schwannoma patients.

## Result

From the data collection results, eleven CT plan data of vestibular schwannoma patients were obtained from January 2014 to November 2017 as the subjects of the study that were suitable with the inclusion and exclusion criteria. The eleven CT plan data of the subjects were all delineated using MRI fusion with contrast, then planning was carried out with each IMRT-SS, VMAT, and HT, followed by an analysis which was conducted to figure out the differences among these three techniques. In the study subjects

there were eight CT plan data with tumor located on the left and three with tumor located on the right. The mean PTV was calculated in eleven subjects and the result was 8.23 cm<sup>3</sup>, with the highest PTV value of 16.2 cm<sup>3</sup> and the lowest of 1.8 cm<sup>3</sup> (**Table 1**).

The SRS dose given for each IMRT-SS, VMAT, and HT techniques was 12 Gy on the margin of PTV, and the prescribed dose (or the maximum dose in PTV) obtained was 72-78% in the IMRT-SS technique, 74-77% in VMAT technique, and 71-77% in HT technique. After the analysis of the mean prescribed dose obtained by each technique was performed, there were no statistically significant differences ( $p>0.05$ ).

The calculations of mean V100% and V50% as the components of CI and GI were performed (**Table 2**). The mean CI was perfectly 1.00 obtained using all three techniques. The mean GI was obtained the lowest in IMRT-SS technique of 4.30+0.43 and the highest was obtained in HT technique of 4.58+0.78, however, after the comparison analysis of mean V100%, V50%, CI, and GI among the three techniques were performed, there were no significant differences found as seen on **Table 2** ( $p>0.05$ ).

In this study, the calculation of mean maximum dose in critical organs, which were the brainstem, ipsilateral and contralateral cochlea, optic chiasm, and ipsilateral and contralateral optic nerves, was performed. Based on the VS tumor location which starts in the inner ear canal until it spread to reach cerebellopontine angle, critical organ optimization was mainly performed as an effort to preserve the brainstem and ipsilateral cochlea. The mean maximum dose in the brain stem was

**Table 1.** Characteristics of study subjects.

No. Subject	Tumor Location	PTV (cm <sup>3</sup> )
1	Left	14.90
2	Right	16.20
3	Left	2.20
4	Right	1.80
5	Left	4.30
6	Left	10.10
7	Left	6.40
8	Left	14.50
9	Left	6.40
10	Left	8.20
11	Right	5.50
Mean		8.23
St. Deviation		5.08
Min- Max		1.80 – 16.20

**Table 2.** Comparison of mean dosimetry V100%, V50%, CI and GI among IMRT, VMAT, and HT techniques.

Parameter	Techniques			IMRT-SS vs VMAT	IMRT-SS vs HT	VMAT vs HT
	IMRT-SS (mean $\pm$ SD)	VMAT (mean $\pm$ SD)	HT (mean $\pm$ SD)			
V100%	8.23 $\pm$ 5.10	8.15 $\pm$ 4.88	8.14 $\pm$ 4.95	0.493	0.489	0.943
V50%	33.93 $\pm$ 19.64	34.61 $\pm$ 19.84	34.55 $\pm$ 17.72	0.249	0.591	0.950
CI	1.00 $\pm$ 0.03	1.00 $\pm$ 0.03	1.00 $\pm$ 0.00	0.878*	1.000*	0.803
GI	4.30 $\pm$ 0.43	4.38 $\pm$ 0.40	4.58 $\pm$ 0.78	0.273	0.091*	0.398*

\* Variable with abnormal data distribution and analyzed using Wilcoxon test

obtained the highest using IMRT-SS technique (1175.89+164.35) and the lowest one was obtained using HT technique (1152.91+141.39), whilst the mean maximum dose on the ipsilateral cochlea was obtained the highest in IMRT-SS technique (736.02+346.88) and the lowest in HT technique (701.09+363.33). After the analysis of the maximum dose in critical organs, a significant difference was only seen in the maximum dose on the contralateral cochlea between the IMRT-SS and VMAT techniques.

The results of the comparison analysis for the mean MU and the duration of irradiation among these three techniques showed a significant difference in each group. The mean duration of irradiation was found the longest in the use of HT technique and the shortest was in VMAT technique.

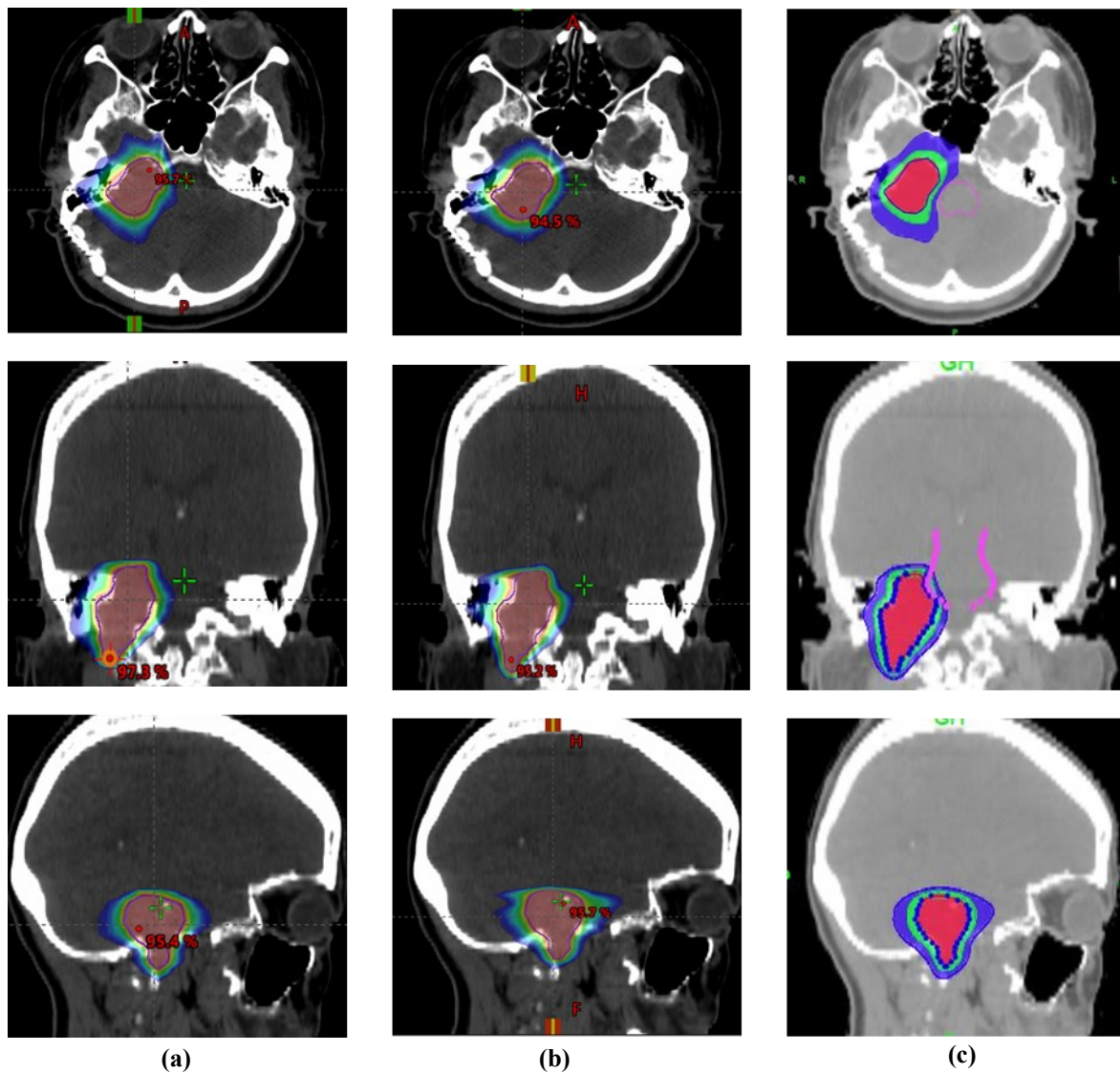
## Discussion

The marginal dose prescribed in this study was 12 Gy in a single fraction. In each SRS technique, optimization was done with a minimum target of 98% PTV which received 98% of the marginal dose. The maximum dose in PTV was adjusted to the prescribed dose. There should not be a serial critical organ which exceeds the threshold as recommended by QUANTEC. The number of fields used in the IMRT-SS technique was 15-17 coplanar fields. The number of arcs used in the VMAT technique were 2 arcs (coplanar and non-coplanar). All HT plans were done with 1.05 cm width, modulation factor value of 2.0 to 3.0, and pitch value of 0.160 to 0.180. Not all planning results met the target of D98% >95% marginal dose due to the limitations on critical organs, particularly the brain stem and ipsilateral cochlea. However, all planning could meet the target of D95% >95% marginal dose.

The mean CI values were similar in the three techniques, which was 1.00, so the IMRT-SS, VMAT, and HT techniques could provide the similar good conformity. This showed that the planning on IMRT-SS and VMAT using MLC blades of 5 mm in this

study could produce SRS planning for the cases of vestibular schwannoma with good conformity. In each group, the range of minimum and maximum CI values in the IMRT-SS technique was 0.96 to 1.09, in the VMAT technique was 0.97 to 1.06, and in the HT technique was 0.97 to 1.04. It was found that although the mean CI value in each group was 1.00, the HT technique provided the narrowest range. This is in accordance with study from Han et al, which stated that CI in HT technique was better than IMRT-SS technique for both coplanar and non-coplanar.<sup>8</sup>

The Gradient Index is an image of steep decreasing dose outside the PTV. The ideal GI value is 1. The greater the GI value means the healthier tissue outside the PTV received 50% of the prescribed dose. There are several factors that influence the magnitude of GI values, including tumor volume, tumor shape, the prescribed dose given and the irradiation techniques. The smaller the tumor volume, the greater the GI value. Irregular shape of the tumor will make it difficult to get a low GI value. The lower the prescribed dose, the lower the GI value, this is expected in SRS planning results.<sup>9</sup> In this study, the lowest mean GI was obtained using IMRT-SS technique and the highest in HT technique, however, this was not statistically significant in all three techniques as seen on **Table 2**. Different results were seen from a study conducted by Han et al which compared GI and duration of SRS irradiation on intracranial tumors using IMRT-SS and HT techniques. The result of the study concluded that in large tumors, both IMRT-SS and HT could provide a comparable GI, however, in small tumors, HT technique was superior in achieving a better GI. This was due to the usage of lower pitch (0.1) in HT technique.<sup>8</sup> In the HT technique, reducing the width of the jaw will increase the beam modulation, reduce the modulation factor, and reduce the pitch size that would slow down the couch speed, allowing better irradiation to the target volume. Compared to the GI of SRS in cases of vestibular schwannoma using Gamma Knife® in the study of



**Figure 1.** Dose distribution on axial, coronal, and sagittal SRS sections in cases of vestibular schwannoma using (a) IMRT-SS (b) VMAT and (c) HT techniques.

Gevaert et al, which was 2.59, GI in the three techniques in this study was still higher.<sup>10</sup> However, it should be noted in the study of Gevaert et al, they did not mention the maximum dose obtained in critical organs like the brain stem and ipsilateral cochlea. According to the results of this study, there were no significant differences of the maximum dose obtained among the critical organs namely the brain stem,

ipsilateral cochlea, optic chiasma, also the ipsilateral and contralateral optic nerves. The priority critical organs which are almost always taken into account in optimization were the brainstem and ipsilateral cochlea (**Table 3**) due to the anatomical location of vestibular schwannoma which originates in the inner ear canal and can extend to the cerebellopontine angle. The HT technique provided the lowest maximum dose to the

**Table 3.** Comparison of mean maximum dose in critical organs among IMRT, VMAT, and HT techniques.

Parameter	Technique			IMRT-SS vs VMAT	IMRT-SS vs HT	VMAT vs HT
	IMRT-SS (mean $\pm$ SD)	VMAT (mean $\pm$ SD)	HT (mean $\pm$ SD)			
Brainstem	1175.89 $\pm$ 164.35	1168.17 $\pm$ 170.42	1152.91 $\pm$ 141.39	0.534*	0.286*	0.657*
Ipsilateral cochlea	736.02 $\pm$ 346.88	734.93 $\pm$ 355.90	701.09 $\pm$ 363.33	0.959	0.790*	0.594*
Contralateral cochlea	174.85 $\pm$ 72.66	122.92 $\pm$ 55.60	170.73 $\pm$ 78.24	0.030	0.895	0.093
Optic chiasm	325.51 $\pm$ 279.32	350.86 $\pm$ 260.52	371.55 $\pm$ 349.44	0.354	0.238	0.614
Ipsilateral optic nerve	230.97 $\pm$ 149.22	267.81 $\pm$ 153.87	233.0 $\pm$ 151.43	0.216	0.916	0.166
Contralateral optic nerve	148.77 $\pm$ 110.20	148.10 $\pm$ 110.57	193.78 $\pm$ 133.53	0.968	0.077	0.078



**Table 4.** Comparison of mean dosimetry MU and duration of irradiation among IMRT-SS, VMAT, and HT techniques.

Parameter	Technique			IMRT-SS vs VMAT	IMRT-SS vs HT	VMAT vs HT
	IMRT-SS (mean $\pm$ SD)	VMAT (mean $\pm$ SD)	HT (mean $\pm$ SD)			
MU	4433.64 $\pm$ 489.30	3628.73 $\pm$ 245.53	15934.45 $\pm$ 4480.15	<0.0001	<0.0001	<0.0001
Beam-on Time	665.05 $\pm$ 73.40	362.87 $\pm$ 24.55	1209.18 $\pm$ 390.20	<0.0001	0.002	<0.0001

brain stem and cochlea (although not statistically significant). This is in accordance to study from Han et al which compared the mean dose and maximum dose obtained by the critical organs in SRS on intracranial tumors between IMRT-SS and HT techniques.<sup>8</sup> From the results of this study, it was concluded that SRS with HT could reach a lower maximum dose in critical organs but provided a higher mean dose due to the wide distribution of irradiation portals in HT technique. From the analysis results, VMAT was significantly superior in reducing the maximum dose obtained by contralateral cochlea compared to IMRT-SS ( $p = 0.03$ ). This was caused by the different configuration of beam directions in the IMRT-SS technique compared to the uniform VMAT technique on the subjects. In the IMRT-SS technique, there were several subjects in which the beam direction was close to the contralateral cochlea, while in the VMAT technique the beam direction seemed to be uniformly further from the contralateral cochlea.

From the results of this study, the duration of irradiation in HT technique was almost twice as long as the duration in IMRT-SS technique and three times longer than the duration in VMAT technique. The duration of the exposure of IMRT-SS was mainly determined by the number of fields and the number of segments. In HT, the duration of irradiation relied on the couch movement speed and the longitudinal dimension of the target. Increasing the width of the jaw might reduce the duration of irradiation but lowering the pitch would not significantly reduce the duration of irradiation because the rotation speed of the gantry would also decrease as the pitch increased to deliver a sufficient dose to the target volume. With a mean duration of HT irradiation of 1209 seconds or equivalent to 20.15 minutes, compared to the duration of irradiation using VMAT technique of 362 seconds or equivalent to 6 minutes, then VMAT technique was more beneficial for patients who will receive therapy.

According to a study conducted by Gevaert et al, duration of SRS irradiation for vestibular schwannoma cases using Gamma Knife® was 68.1 minutes, much longer than the duration of SRS irradiation using

LINAC in all IMRT-SS, VMAT, and HT techniques.<sup>10</sup>

## Conclusions

The three SRS irradiation techniques for cases of vestibular schwannoma, namely IMRT-SS, VMAT, and HT were able to provide the similar good conformity index and did not differ statistically. The lowest GI value, which showed the steepest dose reduction outside the PTV expected from an SRS planning, was obtained by IMRT-SS technique, followed by VMAT, then HT, however, there were no statistically significant GI differences among these three techniques. There were no statistically significant differences in V100% and V50% in the SRS of vestibular schwannoma cases among the IMRT-SS, VMAT, and HT techniques. The maximum dose in SRS of VS cases to the priority critical organs, such as the brainstem and ipsilateral cochlea, was obtained the lowest using HT technique, followed by VMAT, then IMRT-SS, however, there were no statistically significant differences. There were advantages of the VMAT technique in preserving the contralateral cochlea compared to IMRT technique. There were no significant differences in the maximum dose obtained by the optic chiasm and also the ipsilateral and contralateral optic nerves in all three techniques. The total MU and duration of irradiation using VMAT technique were lower and statistically very significant compared to IMRT-SS and HT techniques. This showed the superiority of the VMAT technique in SRS irradiation which tended to have a long duration. The HT technique had the highest total MU and duration of irradiation among the three techniques being studied. The duration of irradiation in HT was almost twice longer than the IMRT-SS, and almost four times the duration of irradiation in VMAT technique.

The VMAT technique can be used as the main choice for SRS management in cases of vestibular schwannoma considering that it could provide conformity and gradient index as good as IMRT-SS and HT techniques, and particularly because it gave shorter duration of irradiation than IMRT-SS and HT, which in turn would increase the comfort for patients.

**Acknowledgment**

This research did not receive any specific grant from funding agencies in the public, commercial, or not-for-profit sectors.

**Financial Support**

This research received no specific grant from any funding agency, commercial, or not-for-profit sectors

**Conflicts of Interest**

None declared.

**Ethical Standard**

The authors assert that all procedures contributing to this work comply with the ethical standards of the relevant national guides on the care of and the use of material and has been approved by committee.

**References**

1. Babu R, Sharma R, Bagley JH, Hatef J, Friedman AH, Adamson C. Vestibular schwannomas in the modern era: epidemiology, treatment trends, and disparities in management. *J Neurosurg.* 2013;119(1):121–30.
2. Berkowitz O, Iyer AK, Kano H, Talbott EO, Lunsford LD. Epidemiology and environmental risk factors associated with vestibular schwannoma. *World Neurosurg.* 2015;84(6):1674–80.
3. Talfer S, Dutertre G, Conessa C, Desgeorges M, Poncet JL. Surgical treatment of large vestibular schwannomas (stages III and IV). *Eur Ann Otorhinolaryngol Head Neck Dis.* 2010;127(2):63–9.
4. Linkov F, Valappil B, McAfee J, Goughnour SL, Hildrew DM, McCall AA, et al. Development of an evidence-based decision pathway for vestibular schwannoma treatment options. *Am J Otolaryngol.* 2017;38(1):57–64.
5. Badakhshi H. Vestibular Schwannoma. In: *Image-guided stereotactic radiosurgery high precision, non-invasive treatment of solid tumor.* Switzerland: Springer;2016. p. 63–80.
6. Song CW, Kim MS, Cho LC, Dusenbery K, Sperduto PW. Radiobiological basis of SBRT and SRS. *Int J Clin Oncol.* 2014;19(4):570–8.
7. Badakhshi H. Radiobiological postulates for the effectiveness of radiosurgery. In: *Image-guided stereotactic radiosurgery high precision, non-invasive treatment of solid tumor.* Switzerland: Springer; 2016. p. 29–46.
8. Han C, Liu A, Schultheiss TE, Pezner RD, Chen YJ, Wong JYC. Dosimetric comparisons of helical tomotherapy treatment plans and step-and-shoot intensity-modulated radiosurgery treatment plans in intracranial stereotactic radiosurgery. *Int J Radiat Oncol Biol Phys.* 2006;65(2):608–16.
9. Paddick I, Lippitz B. A simple dose gradient measurement tool to complement the conformity index. *J Neurosurg.* 2006;105 Suppl:194–201.
10. Collen C, Ampe B, Gevaert T, Moens M, Linthout N, De Ridder M, et al. Single fraction versus fractionated linac-based stereotactic radiotherapy for vestibular schwannoma: A single-institution experience. *Int J Radiat Oncol Biol Phys.* 2011;81(4):503–9.